

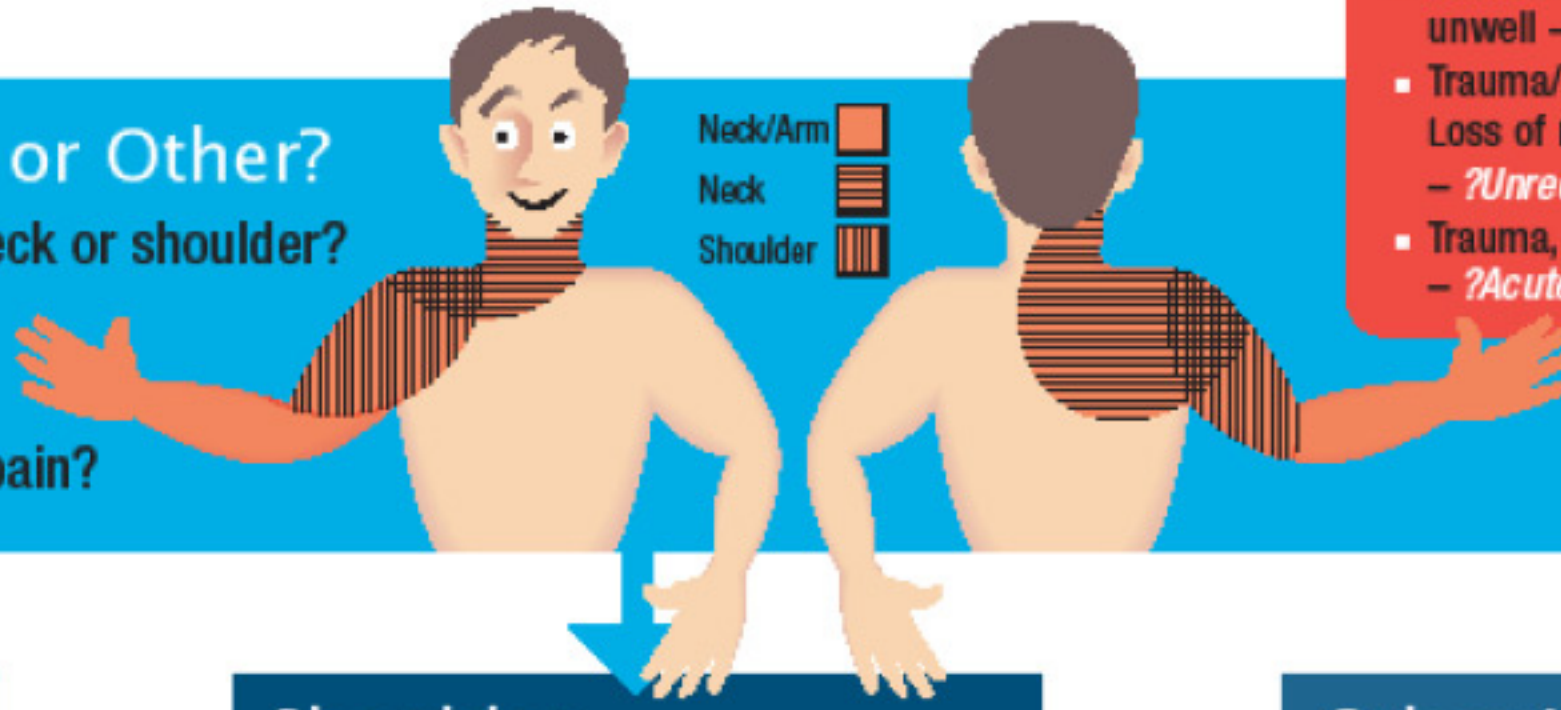
Diagnosis of shoulder problems: With guidelines for initial management

Red Flags – urgent referral

- Any mass or swelling – ?*Tumour*
- Red skin, fever or systemically unwell – ?*Infection*
- Trauma/epileptic fit /electric shock
Loss of rotation and abnormal shape – ?*Unreduced dislocation*
- Trauma, pain and weakness – ?*Acute cuff tear*

Neck or Shoulder or Other?

- Symptoms localised to neck or shoulder?
- Move the neck and then the shoulder.
- Does this reproduce the pain?



Neck

Common Age 35+

Management

- Perform neurological examination. If positive findings then refer
- Rest
- NSAIDS/analgesia
- Physiotherapy

Shoulder

History of instability?

- Has your shoulder ever partly or completely come out of joint?
- Are you worried that your shoulder may dislocate or slip in the joint on sporting activity or on certain movements?

Yes
to one
or both

No
to both

Other Neck or Arm

Common Age 35+

Management

- Rest
- NSAIDS
- Physiotherapy

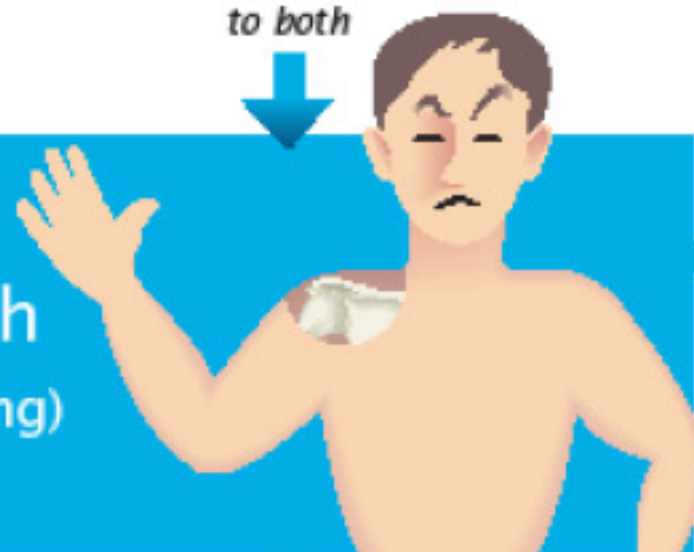
Instability

Common Age 10–35 years

Management

- Refer
- Surgery

Is the pain localised to the AC joint and associated with tenderness? (There may be swelling)



Yes

No

Acromioclavicular Joint Disease

Uncommon
Common Age 30–50 years

Management

- Rest
- NSAIDS/analgesia
- Consider Cortisone Injection
- Refer
- Surgery

Reduced Passive External Rotation



Yes

No

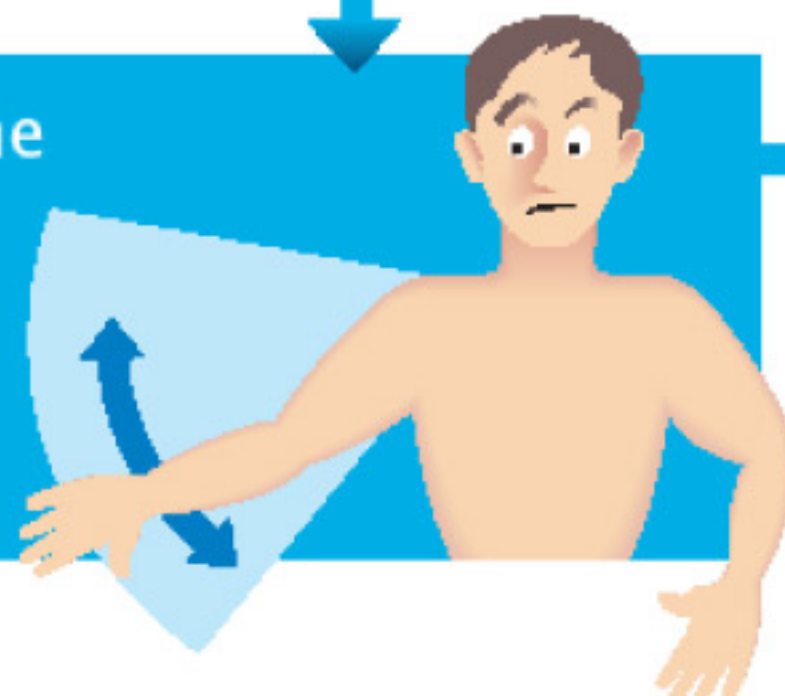
Glenohumeral Joint

Frozen Shoulder Common Age 40–60 years
Arthritis Uncommon
Common Age 60+

Management

- Rest
- NSAIDS/analgesia
- X ray
- Cortisone injection
- Refer
- Surgery

Pain on abduction with the thumb down
Worse against resistance
Painful arc



Yes

No

Rotator Cuff/Impingement

Common Age 35–75 years

Management

- Rest
- NSAIDS/analgesia
- Cortisone injection
- Consider Physiotherapy
- Refer
- Surgery

Other Neck or Arm pain

Common Age 35–75 years

Management

- Rest
- NSAIDS/analgesia
- Physiotherapy
- Refer

HAMPSHIRE SHOULDER CLINIC

**Campbell
Hand**

Consultant Shoulder Surgeon
www.campbellhand.co.uk Tel: 02380 914423
Adapted with kind permission of Oxford Shoulder and Elbow Clinic